

CASE REPORT

Skeletal Anchorage for Class II Correction in a Growing Patient

ANAMARIA MUNOZ, DDS, MS
GIULIANO MAINO, MD, DDS
JEFFREY LEMLER, DDS
DAVID KORNBLUTH, DMD

This article describes the use of miniscrews inserted in the zygomatic buttress for skeletal anchorage in a growing adolescent patient with a Class II, division 1 malocclusion.

Diagnosis

A 12-year-old male in the late mixed dentition was referred by his dentist for orthodontic treatment. Initial examination revealed a skeletal and dental Class II malocclusion with a retrognathic mandible, a severe overbite, moderate overjet, and

mild malalignment of both arches, including rotations and generalized spaces in the mandibular arch (Fig. 1). The facial type was hypodivergent. There was a slight Bolton discrepancy of 79% (norm = 77%), due to small maxillary lateral incisors. The anteroposterior position of the upper lip was within normal limits.^{1,2} The patient had a history of trauma to the maxillary left central incisor, as confirmed by the panoramic radiograph.

Cephalometric analysis (Fig. 2, Table 1) revealed a Class

II, division 1 skeletal malocclusion (ANB = 6°) with a low mandibular plane angle (GoGn-SN = 28°, FMA = 18°), reflecting a low-angle facial pattern and a procumbent interincisal angle (U1-L1 = 128°). The maxilla was slightly protrusive (SNA = 83°), while the mandible was retrusive (SND = 73°, ANB = 6°).

Facial esthetic analysis showed 4mm of upper lip protrusion with respect to the vertical line passing through subnasale (compared with Gianelly and Dietz's reported normal range in



Dr. Munoz



Dr. Maino



Dr. Lemler



Dr. Kornbluth

Dr. Munoz is Clinical Assistant Professor and Dr. Kornbluth is Clinical Associate Professor, Department of Orthodontics, and Dr. Lemler is Clinical Associate Professor, Departments of Postgraduate Periodontics and Postgraduate Implantology, New York University College of Dentistry, New York. Dr. Lemler is also in the private practice of periodontics and implantology in New York. Dr. Kornbluth is also in the private practice of orthodontics in Aventura, FL. Dr. Munoz is also in the private practice of orthodontics at 57 E. 75th St., New York, NY 10021; anamaria.munoz@nyu.edu. Dr. Maino is a Visiting Professor, Parma University, Italy, and in the private practice of orthodontics in Vicenza, Italy.

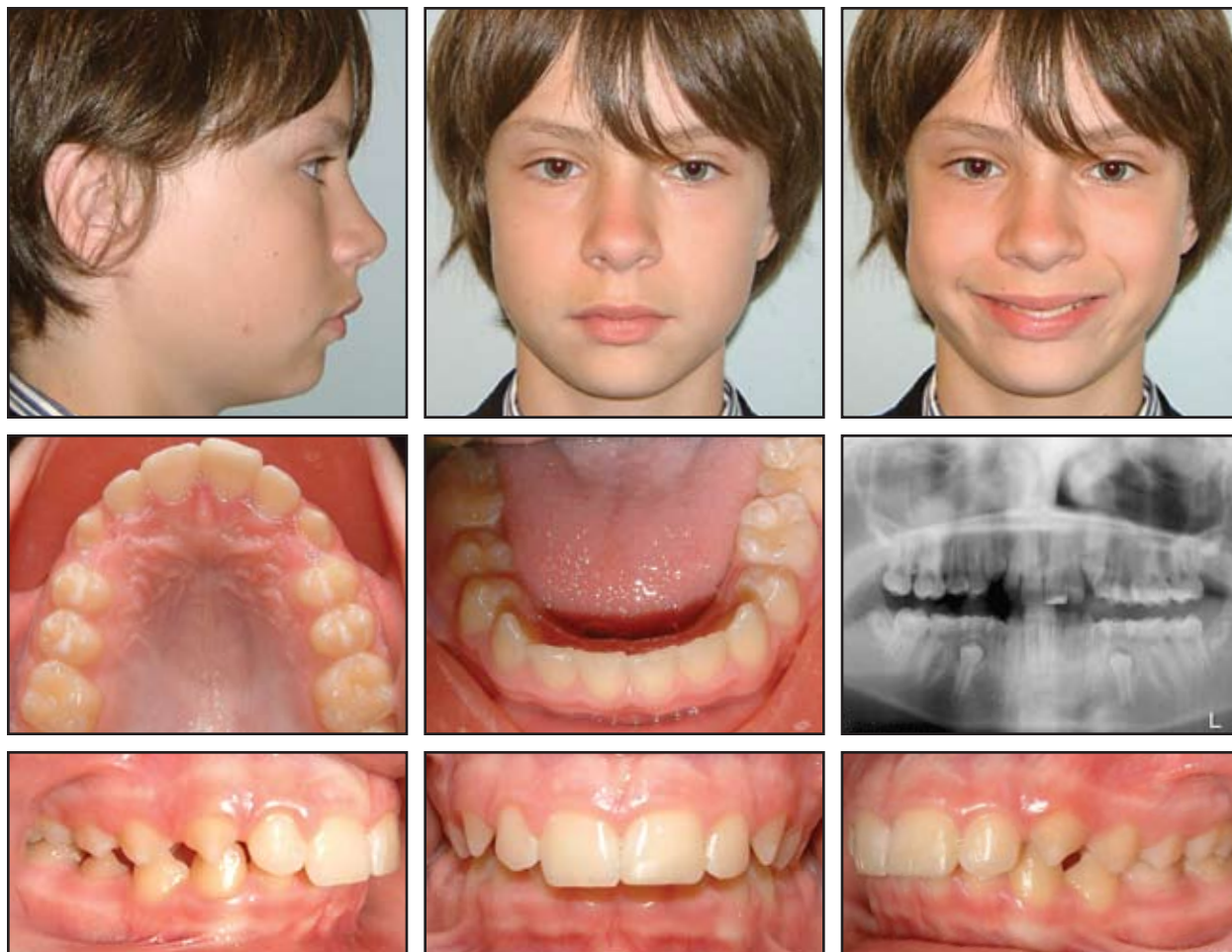

Fig. 1 12-year-old male patient with skeletal and dental Class II malocclusion.

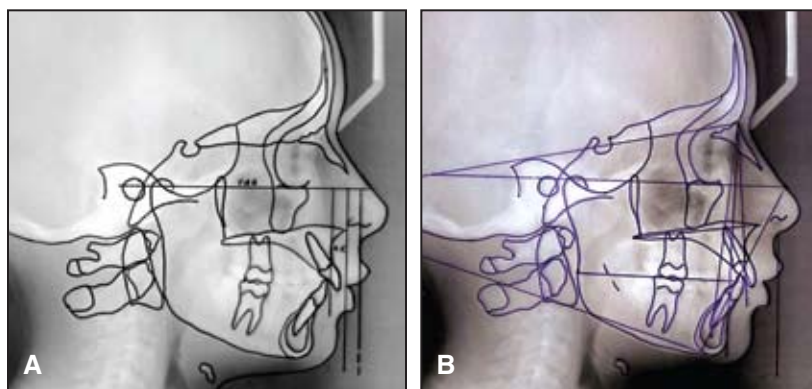


Fig. 2 A. Pretreatment cephalometric tracing. B. Bass esthetic analysis.

males of 2-3mm¹), as well as mandibular retrusion (Fig. 2A). Bass esthetic analysis² showed upper lip protrusion, mandibular retrusion, and the need for upper lip retraction and mandibular advancement to achieve a good profile (Fig. 2B). The body and ramus of the mandible were normal; the symphysis was small, and pogonion indicated a skeletal chin deficiency.

TABLE 1
CEPHALOMETRIC DATA (STEINER, ASE, TWEED)

	Norm	Pretreatment	Progress	Post-Treatment
SNA	82°	83°	83°	83°
SNB	80°	77°	78°	79°
ANB	2°	6°	5°	3°
SND	76/77°	73°	74°	76°
GoGn-SN	32°	28°	32°	32°
Occlusal plane-SN	14°	11°	12°	13°
U1-NA	4.0mm	4.0mm	4.0mm	2.0mm
U1-NA	22°	21°	22°	22°
L1-NB	4.0mm	5.0mm	3.0mm	3.0mm
L1-NB	25°	25°	25°	25°
Pog-NB	—	0.0mm	0.0mm	1.5mm
Po-1-NB (Difference)	—	—	—	-1.5
Interincisal angle	131°	128°	129°	130°
SN-ANS/PNS	8°	4°	5°	4°
ANS/PNS-GoGn	25°	25°	27°	25°
ANS/PNS-U1	110°	108°	108°	109°
Overjet	3.5mm	3.5mm	4.0mm	3.5mm
Overbite	2.0mm	3.5mm	5.0mm	2.0mm
FMIA	65°	63°	64°	64°
FMA	25/27°	18°	20°	20°
IMPA	90°	99°	90°	94°
Sn	—	54.0mm	56.0mm	56.0mm
GoGn	—	55.0mm	60.0mm	62.0mm

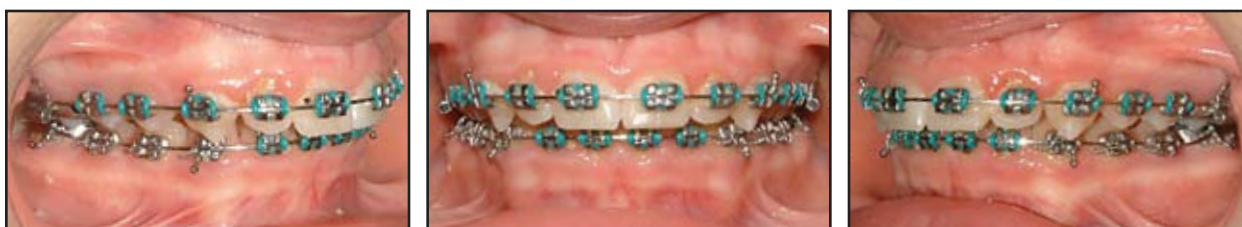

Fig. 3 After nine months of unsuccessful headgear treatment, before miniscrew insertion.

Treatment Plan

The primary treatment objectives were to reduce the overbite, to achieve a Class I posterior

occlusal relationship with bilateral canine occlusion and premolar guidance, and to improve the esthetics of the smile and profile while allowing for mandibular

growth. Both esthetic analyses indicated a need to restrain the maxillary arch while advancing the mandible. Given the patient's age, which ruled out orthognathic

surgery, and hypodivergent facial type, three different options were considered:

1. A two-stage treatment process beginning with orthopedic stimulation of mandibular growth, followed by treatment with fixed appliances.
2. Single-stage orthodontic treatment with fixed appliances, using cervical traction to retract the maxillary teeth.
3. Single-stage orthodontic treatment with fixed appliances after extraction of the maxillary first premolars.

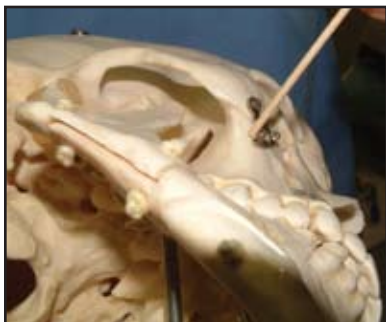

Fig. 4 Anatomical location of miniscrews.

The first option, which might have required the use of an activator and headgear, would have demanded significant patient cooperation and an extended treatment time and was rejected by the patient and his parents. The third option was undesirable, because first premolar extractions in a patient with a hypodivergent facial type can worsen a deep bite, and attempting to open the bite could have led to excessive intrusion of the maxillary incisors.

Studies have shown that the mean difference in mandibular growth between an orthopedic approach and standard orthodontic treatment with fixed appliances is only about 1mm.³ Given the patient's age and hypodivergent facial type, some remaining mandibular growth was expected. Therefore, the second plan, involving Class II nonextraction treatment with fixed appliances, was selected. It was explained to the patient and his parents that because of the skeletal discrepancy, treatment would require full

fixed edgewise appliances combined with cervical headgear, and that a lack of complete cooperation or an inadequate response to treatment might require a different approach involving the use of miniscrews, extraction of the maxillary first premolars, or surgery after the completion of growth.

Treatment Progress

Bidimensional brackets were bonded simultaneously in both arches, with .018" × .025" slots on the incisors and .022" × .028" slots on the canines, premolars, and molars.^{4,6} The mandibular anterior brackets acted as a bite plate to help open the bite. Initially, .016" × .022" stainless steel wires were placed in both arches for leveling and alignment to improve the incisor angulation and open the bite. The maxillary wire was cinched so that the cervical headgear would apply a distal orthopedic force to the maxilla, allowing mandibular growth to reduce the skeletal discrepan-

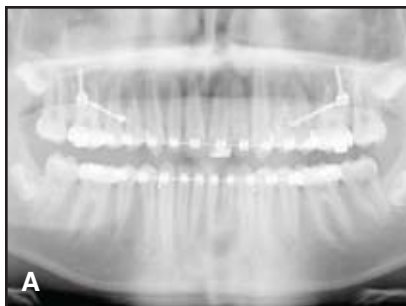

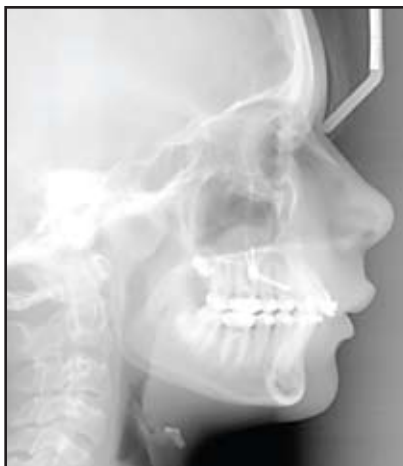Fig. 5 A. After miniscrew insertion. B. Cephalometric tracing with miniscrews in place.

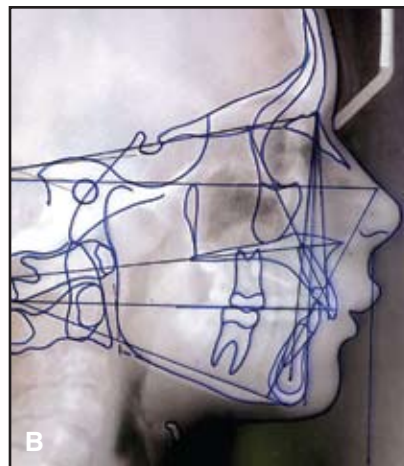

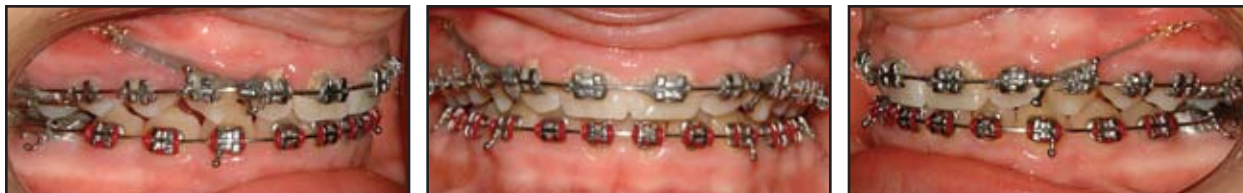


Fig. 6 Six months after miniscrew insertion.

cy.⁷ Class II elastics were used for three months to help close the mandibular spaces, then discontinued to avoid flaring of the mandibular anterior teeth.

Headgear therapy was used for nine months, but compliance was poor, and the patient did not respond to motivational efforts (Fig. 3). After discussion of various treatment options, including Nance and Herbst* appliances and extraction of the maxillary first premolars, miniscrew insertion at the maxillary buttress for skeletal anchorage was recommended. Despite the invasiveness of this procedure compared with the other options, the patient and his parents agreed with the alternative plan.

After making mucogingival incisions on the zygoma along the mesial wall of the maxillary sinus, above the maxillary right and left first molars, a periodontist inserted a cylindrical, 9.5mm Spider Screw** with an attached gold chain on each side (Fig. 4). Radiographs taken after miniscrew insertion at the time of initial force application showed no

major skeletal changes, confirming the lack of efficacy of the headgear therapy (Fig. 5).

For immediate force loading, power thread was attached from the gold chain connected to the miniscrew to a sliding hook cinched on the maxillary archwire between the canine and lateral incisor. A full Class I occlusion was achieved in six months on the right side and in three months on the left side (Fig. 6). New .016" × .022" stainless steel archwires that incorporated the fully erupted second molars were used for finishing and detailing.

Brackets were removed after 25 months of active treatment, and thermoformed upper and lower retainers were fabricated for full-time wear. Two weeks later, a maxillary wraparound retainer and a mandibular Hawley retainer with occlusal rests on the first molars were delivered. The patient was instructed to wear them full-time for the first six months and only at night thereafter, gradually decreasing wear to every other night and then to one or two nights per week after the second year. The patient was told that if he felt any pressure, he should increase the frequency of wear, and that using the retainers indefinitely would help maintain the new tooth positions.⁵

Treatment Results

Despite the poor patient cooperation, all the original treatment objectives were achieved. The facial harmony and lip support were improved, the smile was made more esthetic by broadening the maxillary and mandibular arches, and Class I canine and molar relationships were produced on both sides (Fig. 7). The dental midlines were aligned with the facial midline, and ideal overbite and overjet were achieved. The final panoramic radiograph confirmed proper space closure (disregarding the band spaces, since the radiographs were taken on the day of debonding) and acceptable root parallelism (except for the maxillary right lateral incisor and canine).

Post-treatment cephalometric analysis (Fig. 8) and superimposition of pre- and post-treatment cephalometric tracings (Fig. 9) showed skeletal changes in both arches, as would be expected in a growing patient, with favorable downward and forward mandibular growth (Table 1). The lower anterior facial height, the Frankfort mandibular plane angle, and the GoGn-SN angle were slightly increased, reflecting the downward rotation of the mandible.

*Registered trademark of Dentaaurum, Inc., 10 Pheasant Run, Newtown, PA 18940; www.dentaaurum.com.

**Registered trademark of HDC Company, Via dell'Industria 11, 36016 Sarcedo, Italy; www.hdc-italy.com. Distributed by Ortho Technology; www.orthotechnology.com.

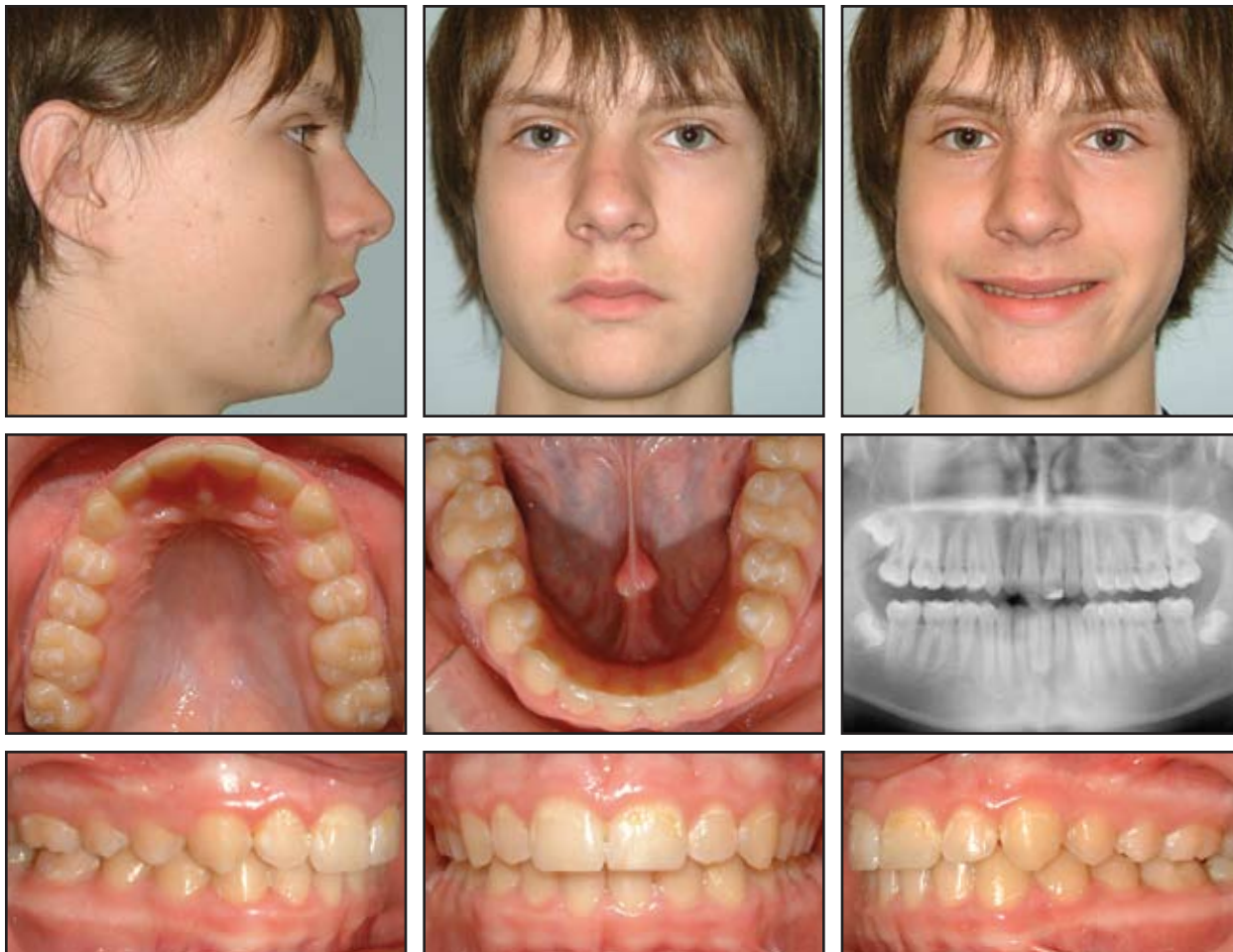


Fig. 7 Patient after 25 months of treatment.

Discussion

In this case, skeletal anchorage at the zygoma above the maxillary molars proved a good alternative to the initial cervical headgear therapy, which was hindered by poor patient cooperation. The white spots and gingival inflammation seen on the post-treatment photographs are further

indications of this poor compliance (Fig. 7).

Steps taken to ensure long-term stability of the treatment results included the maintenance of the intercanine dimension, the establishment of root parallelism, and the recommendation of indefinite night-time wear of wrap-around retainers.⁸ Stability of the overbite correction remains a con-

cern. During mandibular space closure, a reverse curve of Spee was applied in the mandibular arch to maintain the bite opening. Slight intrusion of the incisors and extrusion of the molars were observed, in accordance with the findings of Mitchell and Stewart,⁹ and the overbite can be expected to relapse by 20-40%.^{10,11}

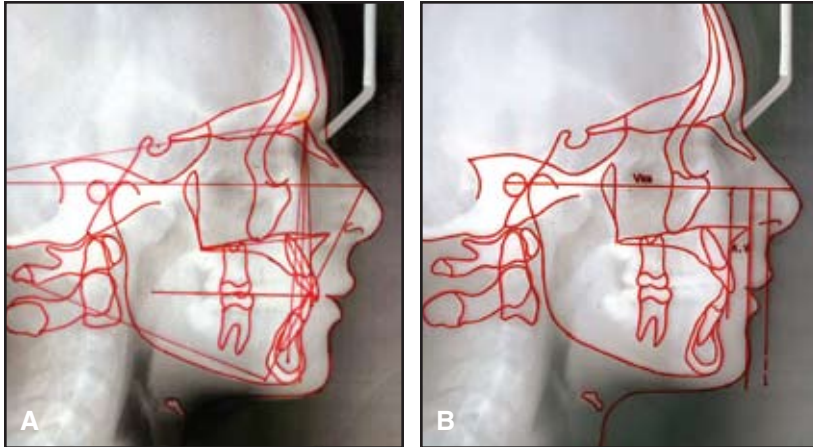


Fig. 8 A. Post-treatment cephalometric tracing. B. Bass esthetic analysis.

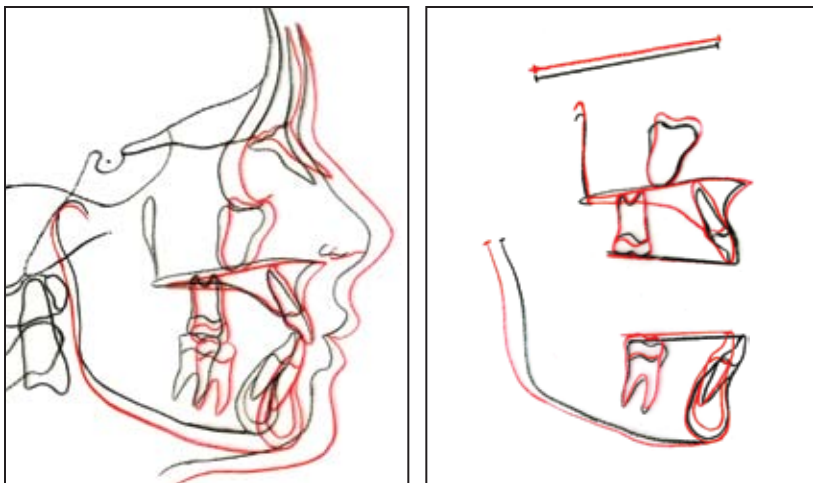


Fig. 9 Superimpositions of pre- and post-treatment cephalometric tracings.

REFERENCES

1. Gianelly, A.A. and Dietz, V.S.: Maxillary arch considerations in diagnosis and treatment planning, *J. Clin. Orthod.* 16:168-172, 1982.
2. Bass, N.M.: The aesthetic analysis of the face, *Eur. J. Orthod.* 13:343-350, 1991.
3. Keeling, S.D.; Wheeler, T.T.; King, G.J.; Garvan, C.W.; Cohen, D.A.; Cabassa, S.; McGorray, S.P.; and Taylor, M.G.: Anteroposterior skeletal and dental changes after early Class II treatment with bionators and headgear, *Am. J. Orthod.* 113:40-50, 1998.
4. Gianelly, A.A.; Bednar, J.R.; and Dietz, V.S.: A Bidimensional edgewise technique, *J. Clin. Orthod.* 19:418-421, 1985.
5. Gianelly, A.A.; Bednar, J.B.; Cociani, S.; Giacotti, F.; Maino, G.; and Richter, O.: *Bidimensional Technique Theory and Practice*, GAC International, Central Islip, NY, 2000.
6. Schudy, F.F. and Schudy, G.F.: The bimetric system, *Am. J. Orthod.* 67:57-91, 1975.
7. Kirjavainen, M.; Kirjavainen, T.; and Haavikko, K.: Changes in dental arch dimensions by use of an orthopedic cervical headgear in Class II correction, *Am. J. Orthod.* 111:59-66, 1997.
8. Little, R.M.; Wallen, T.R.; and Reidel, R.A.: Stability and relapse of mandibular anterior alignment—First premolar extraction cases treated by traditional edgewise orthodontics, *Am. J. Orthod.* 80:349-365, 1981.
9. Mitchell, D.L. and Stewart, W.L.: Documented leveling of the lower arch using metallic implants for reference, *Am. J. Orthod.* 63:526-532, 1973.
10. Burzin, J. and Nanda, R.: The stability of deep overbite correction, in *Retention and Stability in Orthodontics*, ed. R. Nanda and C.J. Burstone, W.B. Saunders, Philadelphia, 1993, pp. 61-79.
11. Berg, R.: Stability of deep overbite correction, *Eur. J. Orthod.* 5:75-83, 1983.